

# Case study

## MANAGEMENT OF AN INFECTED MIDDERMAL friction burn

Byrnes J

*This case study was a winning entry in the inaugural Paul Hartmann/AWMA Advanced Wound Care Course Scholarships in 2006. Winners were chosen following a rigorous assessment process by members of the AWMA Executive Committee and AWMA Education and Professional Development Subcommittee.*

### Presentation

Mr T, a 39 year old male, was in a high-speed (180kmph) motorcycle racing accident. On impact, he broke both wrists and slid for approximately 150 metres before stopping. In this time, his leather race suit burst open along the hip protection seam, exposing his hip to the tarmac for an extended period of time (Figure 1). As a result, he suffered a mid dermal friction burn on the right hip.

Mr T was well educated and was employed as a social worker. He had a good understanding of the implications of his accident and the need for diligent care in the management of his wound in order for it to heal successfully. He lived in a unit with his partner who was very supportive. His mother also lived close by and he enjoyed a great social network within his sport of motorcycle racing and his road-riding club.

### Medical history

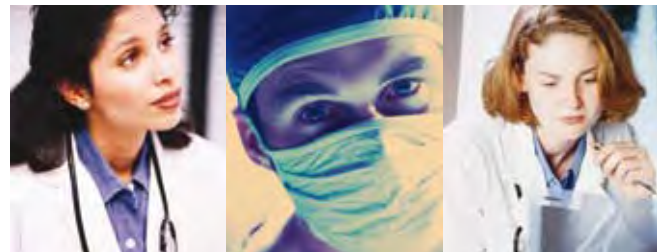
Mr T was healthy, with no other underlying health conditions although he smoked 20-30 cigarettes a day. His alcohol intake was minimal. He was taking Panadine forte™ and Neurophen™ for pain management of the broken wrists.

Jennifer Byrnes  
Wound CNC, Stomal Therapist  
Royal Darwin Hospital NT  
Tel: (08) 89222 8888  
E-mail: Jennifer.byrnes@nt.gov.au

### WOUND PROFILE

On initial presentation to the emergency department, the wound was clean with minimal debris evident. There was a moderate amount of sanguinous exudate. The wound, a friction burn, which measured 10cm x 8.5cm, was located on the right hip.

Day 3 post injury, the wound was mid dermal in depth and had an offensive purulent exudate. At this stage, the infection appeared localised, therefore no wound cultures were taken. Small blisters were evident at the edge of the wound margin (Figure 2).



## RN to MBBS

Work while you study.

- ✦ Flexible Distance Learning MBBS Program
- ✦ Physician Mentors in your Community
- ✦ Dynamic Online Courses and Tutors

At last, a 4 year graduate entry MBBS program that allows you to continue working while you study during your first 2 years. Oceania University of Medicine in Samoa is the choice of nurses and other health professionals advancing their careers as medical doctors.

**Classes Begin January, March, June, August and October each year.**

Further enquiries:

**1300 665 343**

**[www.oceaniamed.org](http://www.oceaniamed.org)**

OUM160905AIC



---

The aim of wound care for this patient was to heal the wound in a timely manner by treating the complications of infection with appropriate wound care management strategies.

On initial assessment, the wound was bleeding, therefore a calcium alginate was applied to aid in haemostasis. This was covered with a secondary foam dressing and secured with Fixomul™. The wound was reviewed 3 days later and was found to be inflamed with raised friable granulation tissue. There was increased pain at the site and erythema was beginning to extend from the initial wound margins; small blisters were also evident. Systemically, he was afebrile, there was no lymph node swelling evident and the erythema was localised.

At this stage it was determined that the aim of wound management was to contain the infection with the use of a topical antimicrobial. If the infection could be treated topically, there may be no need to utilise antibiotics. Topical silver in the form of Acticoat™ was chosen to treat the wound. The Acticoat was applied wet and secured with Fixomul. The client was informed to shower twice daily to keep the dressing moist in accordance with the manufacturer's instructions.

## PROGRESS AND FOLLOWUP

Figure 3 shows the wound 6 days post the initial injury and 3 days since commencement of the Nanocrystalline silver. The friable red tissue was no longer evident and islands of epithelial tissue were present, as were some areas of slough. The exudate was haemoserous and no longer malodorous. There was minimal evidence of erythema surrounding the wound; however, there was silver staining on the peri wound skin. Also noted on the peri wound skin were small pustules due to the adhesive tape used to secure the dressing. A no-sting protective barrier film wipe was applied to the skin to prevent ongoing irritation.

Nine days post injury, epithelial islands were evident and the peri wound skin was free of the pustules noted on the previous dressing change. There was no evidence of erythema, and exudate levels had decreased (Figure 4).

Twelve days post injury, the wound continued to heal in a timely manner with minimal slough evident. Acticoat was ceased at this stage and Fixomul was applied for protection and for the final stages of wound healing. This was left intact for 7 days. Perforated adhesive tapes such as Fixomul can be used as primary semi occlusive dressings to aid healing and

reduce scarring in superficial burn wounds<sup>1</sup> (Figure 5).

Nineteen days post injury, the wound was healed. The patient was advised to moisturise the area daily to keep the skin supple and prevent new skin from drying out, cracking or breaking down. Three months post injury the site remains healed (Figure 6).

## Discussion

Generally, when there are indications of wound infection, not colonisation, systemic antibiotics are administered to the patient after taking wound swabs or tissue biopsies to identify causative bacteria and bacterial sensitivities to the various antibiotics. In this patient's case, the wound was still in the early stages of wound healing; it could be classed as still being in the inflammatory phase which lasts from 0-3 days<sup>2</sup>. However, it was possible to identify that the wound was infected due to the malodorous exudate; malodour is a sign of infection not inflammation<sup>2</sup>. As this diagnosis was made without the benefit of wound swabs, there was no identification of the exact bacteria causing the infection.

Due to this, a decision was made to use a silver-based dressing to reduce infection instead of using antibiotics as first line management of infection. Silvers are broad-spectrum antimicrobials which are now used in a variety of different forms<sup>2</sup>. Silver dressings are primarily indicated for the management or prevention of soft tissue infections<sup>3</sup>.

Acticoat was chosen due to its effectiveness on over 150 pathogens, including Gram-positive and Gram-negative bacteria and fungal wound pathogens, plus antibiotic-resistant bacteria such as *Pseudomonas*, Methicillin-resistant *Staphylococcus aureus* (MRSA) and Vancomycin-resistant *Enterococcus* (VRE)<sup>4</sup>. The nanocrystalline sheet was deemed to be the best choice as it provided broad coverage of the possible pathogens that could be causing complications in this wound. Acticoat also has anti-inflammatory properties which it was thought could be highly beneficial for this wound<sup>5</sup>.

This strategy proved successful, as demonstrated in the photos (Figures 2-6). It is possible to suggest from this case that nanocrystalline silver could be used prior to antibiotics and may possibly negate the need for antibiotics if the infection subsides whilst using this particular silver dressing. Nanocrystalline silver has been demonstrated here to be effective on localised infection but, as this is only one case, no definitive outcomes can be taken from this case study alone.

Nanocrystalline silver was used to combat infection and promote healing in this mid dermal friction burn wound. It was successful in both accounts. The peri wound skin was also monitored and treated with a no-sting barrier film wipe to prevent further skin irritation occurring. Since Mr T was a fit, healthy man, there were no other complications that arose from his accident. His wound infection was possibly due to the mechanism of the injury, i.e. friction with and local contaminants from the road surface. The wound management strategies used allowed the wound to heal in a timely manner. The localised infection was treated when it first presented in order for it to not delay wound healing.

## 2ECOMMENDATIONS

Further research is required to identify if nanocrystalline silver and indeed all forms of silver could be used as the initial treatment of infection prior to the administration of antibiotics. This may reduce the need for systemic antibiotics, which in turn may reduce the resistance of bacteria due to the overuse of antibiotics as we have seen in past management of bacterial and viral infections.

## Declaration

Products used to treat the patient in this case study were not supplied by the manufacturer.

## 2EFERENCES

1. Sylaidis P, Clibbon J, Eagling V & King C. Removal of a perforated adhesive tape: dry verses solvent assisted. *J Wound Care* 2001;
2. Carville K. *Wound Care Manual*. Perth WA: Silver Chain Nursing Association, 2005.
3. Thomas S & McCubbin P. An in vitro analysis of the antimicrobial properties of 10 silver-containing dressings. *J Wound Care* 2003;
4. Acticoat with Silcryst Nanocrystalines. Smith & Nephew company product information brochure, January 2003.
5. Burrell R. Lecture at the Smith & Nephew Silver symposium. Melbourne July 2005.



Figure 1. Friction on leather prior to friction on skin.

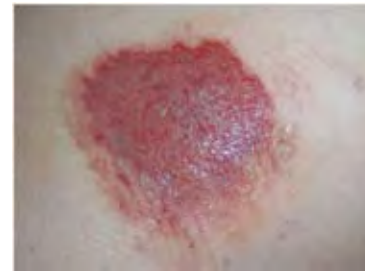

Figure 2. Three days post initial injury.

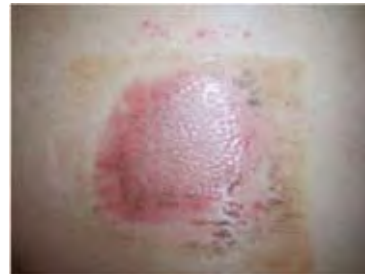

Figure 3. Day 6.

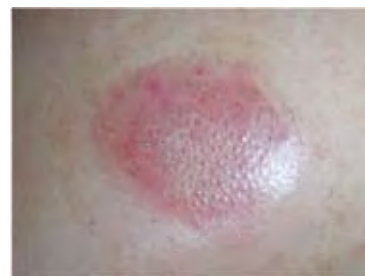

Figure 4. Day 9.

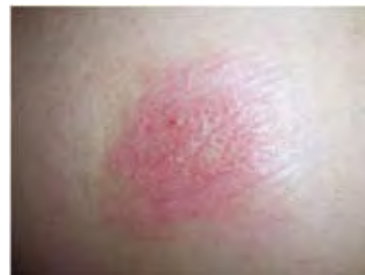

Figure 5. Day 12.

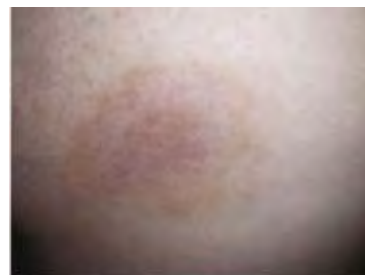

Figure 6. Three months post injury.